

Efficacy of anti-programmed cell death-1 immunotherapy for skin carcinomas and melanoma metastases in a patient with xeroderma pigmentosum

G. Salomon,^{1,2} A. Maza,^{1,2,3} S. Boulinguez,^{1,2} C. Paul ^{1,2} L. Lamant,⁴ E. Tournier,⁴ J. Mazereeuw-Hautier^{1,2,3} and N. Meyer ^{1,2}

¹Dermatology, Paul Sabatier-Toulouse III University, Institut Universitaire du Cancer de Toulouse, Toulouse, France

²CHU de Toulouse, Larrey Hospital, Toulouse, France

³Reference Center for Rare Skin Diseases, Toulouse, France

⁴Pathology, University Cancer Institute of Toulouse, Toulouse, France

Linked Comment: Kraemer *et al.* *Br J Dermatol* 2018; **178**:1009.

Summary

Correspondence

Nicolas Meyer.

E-mail: meyer.n@chu-toulouse.fr

Accepted for publication

15 December 2017

Funding sources

None.

Conflicts of interest

N.M. has worked as an investigator and/or consultant and/or speaker for Roche, Novartis, GSK, BMS, MSD, Amgen and Pierre Fabre. S.B. has worked as an investigator and/or consultant and/or speaker for MSD, BMS, Roche and Novartis.

DOI 10.1111/bjd.16270

Xeroderma pigmentosum (XP) is an orphan disease of poor prognosis. We report one case of parallel efficacy with anti-programmed cell death-1 (PD-1) antibody on both melanoma and skin carcinoma in a patient with XP. A 17-year-old patient presented with metastatic melanoma and multiple nonmelanoma skin cancers. He was treated with pembrolizumab, a monoclonal anti-PD-1 antibody, at a dose of 2 mg kg⁻¹, every 3 weeks. Parallel therapeutic efficacy of anti-PD-1 was observed in metastatic melanoma and skin carcinomas, and maintained at week 24. This observation suggests anti-PD-1 may be considered in patients with XP and metastatic melanoma in addition to advanced nonmelanoma skin cancer.

What's already known about this topic?

- Xeroderma pigmentosum (XP) is a rare disease with a poor outcome.
- XP affects nucleotide excision repair, with cutaneous, ocular and neurological manifestations. Management of patients with XP currently includes highly efficient ultraviolet protection and close dermatological follow-up for early detection and treatment of skin carcinomas.

What does this study add?

- We report the efficacy of anti-programmed cell death-1 (PD-1) antibody immunotherapy for skin carcinoma in a patient with XP.
- Anti-PD-1 antibody may improve the prognosis of this rare skin condition.

Xeroderma pigmentosum (XP) is a rare autosomal recessive genetic disease, with an estimated prevalence of 2-3 per 1 000 000 in Western Europe¹ and 1 in 250 000 in the U.S.A.² XP is an orphan disease of poor prognosis, with a median survival of 32 years.³ Patients with XP have a 10 000-fold increased risk of nonmelanoma skin cancer and a 2000-fold risk of melanoma before the age of 20.³ Management of XP currently includes highly efficient ultraviolet (UV) protection and close dermatological follow-up for early detection and treatment of skin carcinomas. Treatment of skin carcinomas in a patient with XP is similar to that of treatment in other patients and may include surgery, chemotherapy and

cautious radiotherapy. To our knowledge, limited data have been reported on the use of immune checkpoint inhibitors such as programmed cell death-1 (PD-1) inhibitors in patients with XP.⁴

Tumour cells expressing the programmed cell death-ligand 1 (PD-L1) inactivate the apoptosis signal received from T lymphocytes. PD-1 inhibitors restore the antitumoral activity of immune cells against tumour cells⁵ and are effective in melanoma, nonsmall cell lung carcinoma, bladder cancer and renal cell carcinoma.⁶⁻⁸ Therapeutic response is currently considered higher in tumours with a high PD-L1 expression level,⁹ virus-induced tumours and also in tumours associated with

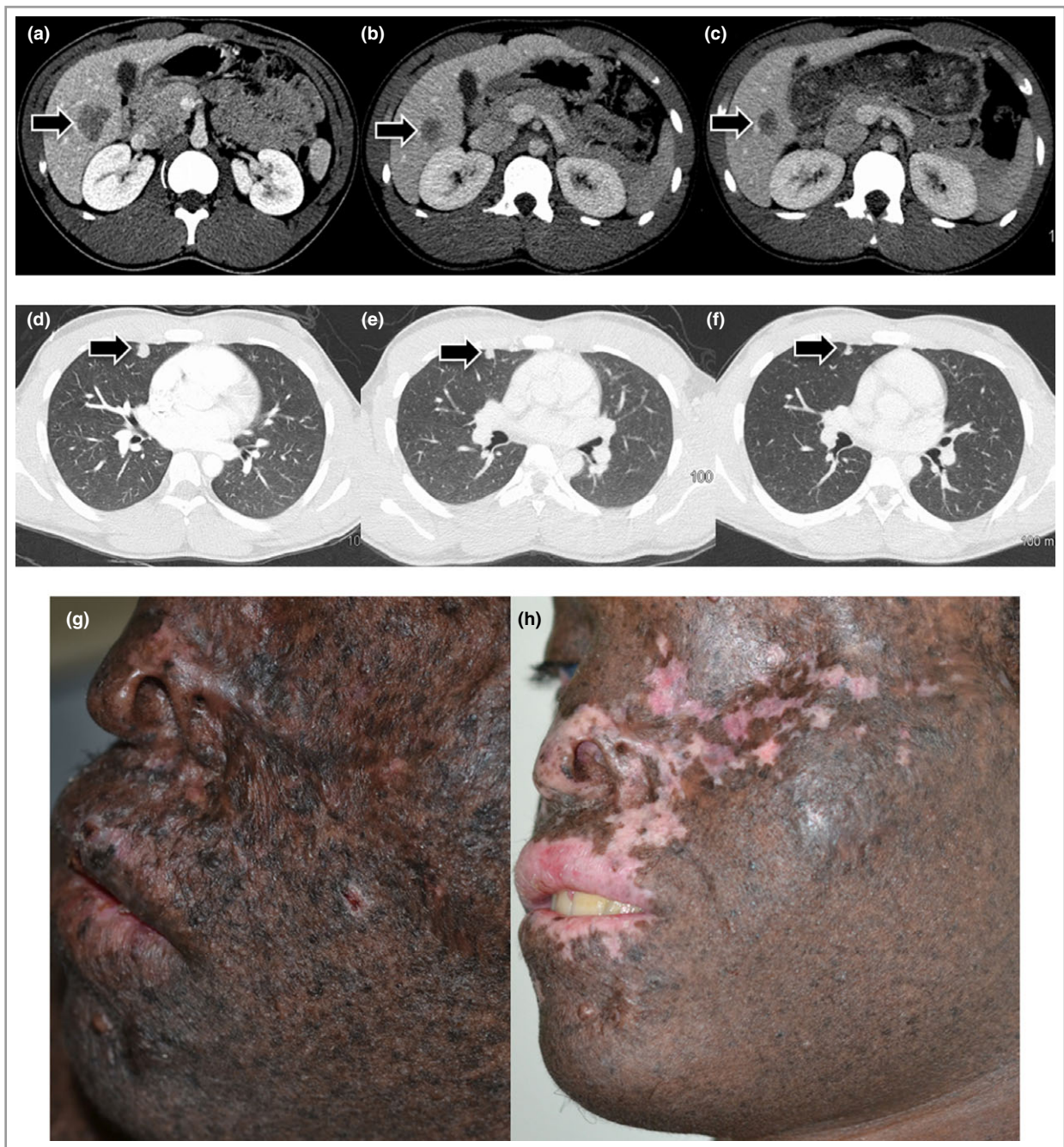


Fig 1. Evolution of metastases and clinical response to treatment. (a) Axial computed tomography (CT) scan with contrast shows the hepatic metastases before treatment measuring 22 × 30 mm (arrow); (b) and (c) after treatment with a programmed cell death-1 (PD-1) inhibitor: axial CT with contrast shows the reduction of the metastases consistent with treatment response after four cycles (b) measuring 17 × 24 mm (arrow) and after eight cycles (c) measuring 13 × 22 mm (arrow); (d) axial CT shows one of the pulmonary metastases before treatment measuring 11 × 11 mm (arrow); (e) and (f) axial CT shows response of the pulmonary metastases after four cycles (e) measuring 6.5 × 8 mm (arrow) and after eight cycles (f) measuring 5.5 × 7.5 mm. (g) Shows skin before treatment and (h) shows the clinical response to treatment after eight cycles with disappearance of cancerous and precancerous lesions, vitiligo depigmentation.

significant mutational load, which increases the amount of tumour neoantigens.¹⁰ We report here the parallel therapeutic efficacy of pembrolizumab, an anti-PD-1 monoclonal antibody in metastatic melanoma and skin carcinomas in a patient with XP.

Case report

A 17-year-old patient was diagnosed with XP at the age of 2 years. He was born in the French Department of Mayotte off the coast of Southeast Africa and had been followed in our

national reference centre for rare dermatological diseases for 10 years. UV-protection measures during the first years of life were not fully implemented. The patient, with skin Fitzpatrick phototype VI, presented with solar lentigines, hypopigmented macules and early-onset skin carcinomas. XP type C (XP-C) diagnosis was confirmed by molecular analysis showing homozygous mutations of NM_004628: c2251-1G>C in the XPC gene. This founder mutation is common in Africa.¹¹

In the past 10 years, the patient had been repeatedly treated for multiple skin carcinomas with surgery and/or photodynamic therapy and/or topical chemotherapy with fluorouracil cream. The patient underwent enucleation of the left eye at the age of 12 for squamous cell carcinoma infiltrating the inner canthus and the eye. In 2012, the patient presented with a nodular and ulcerated melanoma of the scalp, Breslow thickness 3.3 mm, mitotic rate 8 mm². A 2-cm-wide enlarged excision was performed. The sentinel lymph node biopsy was free of tumour cells. A follow-up, including abdominal and lymph node ultrasound monitoring, was performed every 6 months.

In January 2016, at the age of 17 years, hepatic metastases were identified and a whole body computed tomography scan showed multiple pulmonary metastases (Fig. 1). The BRAFV600 mutation was not detected in liver tumour cells. The melanoma was staged T4bN0M1c, American Joint Committee on Cancer stage IV with normal lactate dehydrogenase. Physical examination showed numerous actinic keratoses, basal cell and squamous cell carcinomas mostly on the face and limbs (Fig. 1). Pembrolizumab treatment at the dose of 2 mg kg⁻¹ every 3 weeks was initiated according to the decision taken by the multidisciplinary dermato-oncology team.

After four cycles of treatment, a partial response with a decrease in size of metastases was observed (Fig. 1). Physical examination showed vitiligoid depigmentation occurring preferentially on UV-exposed areas, regression of cutaneous carcinomas and disappearance of many pre-existing actinic keratoses.

After eight cycles of treatment, therapeutic efficacy on melanoma and skin carcinomas was maintained (Fig. 1). Pembrolizumab treatment was continued every 3 weeks. Metastases continued to decrease after 12 cycles. In June 2017, the patient was still under treatment and metastases have been stable in size for 6 months. The patient did not have any of the known adverse side-effects of anti-PD-1 therapy such as pneumonitis, colitis, hepatitis, nephritis, rash, hypophysitis, thyroiditis, diabetes or infusion reaction. Immunohistochemistry was used in the melanoma and three different squamous cell carcinomas to analyse lymphocyte expression of CD3 and PD-L1 (Fig. 2).

Discussion

Here we report a parallel therapeutic response of metastatic melanoma and primary cutaneous carcinomas in a patient with XP treated with anti PD-1. A similar case of regression of melanoma lung metastases, multiple basal cell carcinomas and Bowen disease in a patient with XP type E using pembrolizumab has recently been reported by Hauschild *et al.*⁴ Recent publications have reported the efficacy of anti-PD-1 immunotherapy in nonmelanoma skin cancers (Table 1). The effect of anti-PD-1 immunotherapy has been reported for squamous cell carcinoma of the head and neck¹² and anti-PD-1

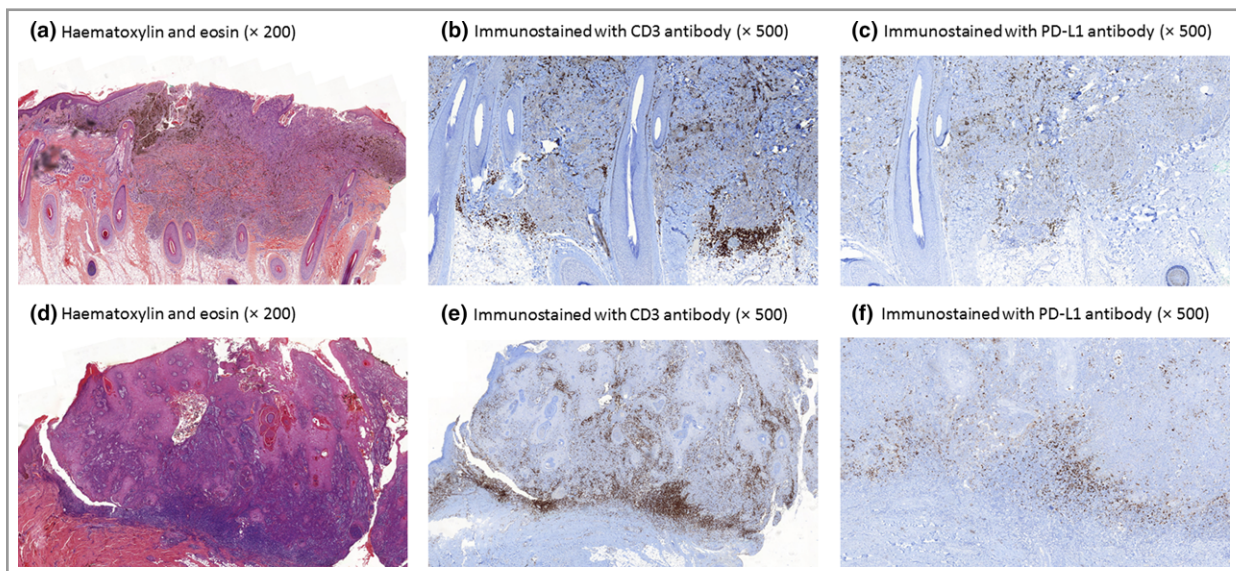


Fig 2. Haematoxylin and eosin, CD3 and programmed cell death-ligand 1(PD-L1) staining on the melanoma and a cutaneous squamous cell carcinoma (SCC). (a) Biopsy specimen of the patient's melanoma prior to treatment with pembrolizumab; (b) and (c) immunostaining of the melanoma shows low abundance of CD3 cells (b) and no expression of PD-L1 (c) on immune and tumour cells; (d) biopsy specimen of one of the SCCs before treatment; (e) and (f) immunostaining of the SCC shows high abundance of CD3 cells (e), strong signal of PD-L1 on the immune cells and no signal of PD-L1 on the tumour cells (f). PD-L1 staining was made using the SP-142 clone.

Table 1 Case reports of immunotherapy in basal cell carcinoma (BCC) or squamous cell carcinoma (SCC)

Author ^a	n	Type of cancer	Treatment	Efficacy
Mohan <i>et al.</i> ^{S1}	1	Nodular BCC (size 9 × 8 cm)	Ipilimumab 3 mg kg ⁻¹ every 3 weeks	Partial response (5 × 7 cm) after 6 weeks
Chang <i>et al.</i> ^{S2}	1	Metastatic SCC	Pembrolizumab 2 mg kg ⁻¹ every 3 weeks	Stable disease after six cycles
Borradori <i>et al.</i> ^{S3}	1	Metastatic SCC	Pembrolizumab 2 mg kg ⁻¹ every 3 weeks	Partial response after 7 months
	1	Metastatic SCC	Nivolumab 3 mg kg ⁻¹ every 2 weeks	Partial response after 7 months
	1	Metastatic BCC	Nivolumab 3 mg kg ⁻¹ every 2 weeks	Stable disease after four cycles
	1	Metastatic SCC	Nivolumab	Stable disease after five cycles
	1	Metastatic SCC	Pembrolizumab	Stable disease after 4 months
Winckler <i>et al.</i> ^{S4}	1	Metastatic BCC	Pembrolizumab	Stable disease
	1	Metastatic SCC	Pembrolizumab	Partial response after 4 months
Schwab <i>et al.</i> ^{S5}	1	Metastatic SCC	Nivolumab 3 mg kg ⁻¹ every 2 weeks	Partial response after 5 months
Ikeda <i>et al.</i> ^{S6}	1	Metastatic BCC	Nivolumab 240 mg every 3 weeks	Partial response after 4 months
Day <i>et al.</i> ^{S7}	1	Metastatic SCC	Ipilimumab	Partial response after 8 months
Lipson <i>et al.</i> ^{S8}	1	Metastatic BCC	Pembrolizumab 2 mg kg ⁻¹ every 3 weeks	Partial response after 14 months
Degache <i>et al.</i> ^{S9}	2	Local advanced SCC	Pembrolizumab 2 mg kg ⁻¹ every 3 weeks	Partial response after six (patient A)
				and four cycles (patient B)
Ravulapati <i>et al.</i> ^{S10}	1	Metastatic SCC	Pembrolizumab	Partial response after seven cycles

^aSuperscript numbers are for the references cited in this table, which can be found in Appendix S1 (see Supporting Information).

immunotherapy has become a major treatment for squamous cell lung cancer.¹³

Eight XP complementation groups have been described [XP-A to XP-G and XP variant (POLH)] that correspond to the affected DNA repair gene. Seven of these genes, XPA to XPG, are involved in nucleotide excision repair, repairing UV-induced damage from DNA. The eighth gene, POLH, codes for DNA polymerase η, which is required for the replication of DNA containing unrepaired UV-induced damage.¹⁴

XP mutations cause DNA repair disorders that promote skin carcinoma, resulting in multiple early skin carcinomas (including melanoma and nonmelanoma skin cancers) with a high mutational load.² A high mutational load is currently suggested as a predictive factor of tumour response to immune checkpoint inhibitors, tumours carrying a high mutational load being probably more inclined to express tumour neoantigens that are specifically recognized by T cells.¹⁰

In our patient, parallel regression of melanoma metastases and skin carcinomas were observed. We hypothesize that the XP may have been the field of skin carcinomas and melanoma carrying a high mutational load, which could participate in the therapeutic response of both the melanoma and skin carcinomas. Interestingly, we also observed that pembrolizumab-induced vitiligo depigmentation was preferentially observed on UV-exposed areas of the skin, once again suggesting a role of UV-induced mutations in the therapeutic response that was observed in this patient.

UV exposure not only induces DNA damage, but also skin immunosuppression.¹⁵ To our knowledge, no data have been reported on the role of UV-induced immune suppression in the development of skin carcinoma in patients with XP. In our patient, UV-induced immune suppression does not seem to be the major pathophysiological mechanism to explain the efficacy of the anti-PD-1 antibody.

In conclusion, we report the parallel therapeutic response of metastatic melanoma and multiple nonmelanoma skin cancers in a patient with XP treated with the anti-PD-1 antibody pembrolizumab. This observation suggests anti-PD-1 may be considered in patients with XP and metastatic melanoma in addition to advanced nonmelanoma skin cancer.

References

- Kleijer WJ, Laugel V, Berneburg M *et al.* Incidence of DNA repair deficiency disorders in western Europe: Xeroderma pigmentosum, Cockayne syndrome and trichothiodystrophy. *DNA Repair* 2008; **7**:744–50.
- Robbins JH, Kraemer KH, Lutzner MA *et al.* Xeroderma pigmentosum an inherited disease with sun sensitivity, multiple cutaneous neoplasms, and abnormal DNA repair. *Ann Intern Med* 1974; **80**:221–48.
- Bradford PT, Goldstein AM, Tamura D *et al.* Cancer and neurologic degeneration in xeroderma pigmentosum: long term follow-up characterizes the role of DNA repair. *J Med Genet* 2011; **48**:168–76.
- Hauschild A, Eichstaedt J, Möbus L *et al.* Regression of melanoma metastases and multiple non-melanoma skin cancers in xeroderma pigmentosum by the PD1-antibody pembrolizumab. *Eur J Cancer* 2017; **77**:84–7.
- Iwai Y, Terawaki S, Honjo T. PD-1 blockade inhibits hematogenous spread of poorly immunogenic tumor cells by enhanced recruitment of effector T cells. *Int Immunol* 2005; **17**:133–44.
- Brahmer JR, Tykodi SS, Chow LQM *et al.* Safety and activity of anti-PD-L1 antibody in patients with advanced cancer. *N Engl J Med* 2012; **366**:2455–65.
- Sharma P, Allison JP. The future of immune checkpoint therapy. *Science* 2015; **348**:56–61.
- Powles T, Eder JP, Fine GD *et al.* MPDL3280A (anti-PD-L1) treatment leads to clinical activity in metastatic bladder cancer. *Nature* 2014; **515**:558–62.
- Gibney GT, Weiner LM, Atkins MB. Predictive biomarkers for checkpoint inhibitor-based immunotherapy. *Lancet Oncol* 2016; **17**:e542–51.

- 10 McGranahan N, Furness AJS, Rosenthal R *et al.* Clonal neoantigens elicit T cell immunoreactivity and sensitivity to immune checkpoint blockade. *Science* 2016; **351**:1463–9.
- 11 Cartault F, Nava C, Malbrunot A-C *et al.* A new XPC gene splicing mutation has lead to the highest worldwide prevalence of xeroderma pigmentosum in black Mahori patients. *DNA Repair* 2011; **10**:577–85.
- 12 Chow LQM, Haddad R, Gupta S *et al.* Antitumor activity of pembrolizumab in biomarker-unselected patients with recurrent and/or metastatic head and neck squamous cell carcinoma: results from the phase Ib KEYNOTE-012 expansion cohort. *J Clin Oncol* 2016; **32**:3838–45.
- 13 Leventakos K, Mansfield AS. Advances in the treatment of non-small cell lung cancer: focus on nivolumab, pembrolizumab, and atezolizumab. *BioDrugs Clin Immunother Biopharm Gene Ther* 2016; **30**:397–405.
- 14 Fassihi H. Spotlight on 'xeroderma pigmentosum'. *Photochem Photobiol Sci* 2012; **12**:78–84.
- 15 Poon TSC, Barnetson RSC, Halliday GM. Sunlight-induced immunosuppression in humans is initially because of UVB, then UVA, followed by interactive effects. *J Invest Dermatol* 2005; **125**:840–6.

Supporting Information

Additional Supporting Information may be found in the online version of this article at the publisher's website:

Appendix S1 References for Table 1.